



PATIENT PRESENTING CLINICAL SIGNS

- Koda Kiefer
- ~ 1 month Hx of left rear lameness; rDVM noted subtle thickening of left stifle.
 - Using NSAID intermittently. During use the lameness improves to normal or near normal, but recurs when off NSAID

SPECIES

Canine
Abnormal PE/Chem/CBC/UA Results: Radiographs: mild sub luxation of left hip; left stifle has mild effusion present. Minimal laxity in left stifle under sedation, subjectively similar to right stifle.

ULTRASONOGRAPHIC STUDY OF THE LEFT STIFLE

BREED

Golden Retriever

ULTRASONOGRAPHIC FINDINGS

SEX

Image quality is mildly limited by imperfect beam penetration, likely related to patient size, skin thickness and acoustic coupling. There is mild synovial thickening and a small volume of anechoic joint effusion.

MN

The cranial cruciate ligament is continuous throughout its visualized length with mild diffuse thickening, but no focal fiber disruption, hypoechoic defects or discontinuities identified.

AGE

The medial meniscus is visualized in situ and appears unremarkable with no obvious displacement or tearing.

2yr

The medial collateral ligament presents mild generalized thickening without evidence of fiber disruption.

INTERPRETED BY

Nele Eley (Ondreka),
DVM Dr. med. vet.,
DipECVDI

No significant osteophyte formation is identified at this time.

ULTRASONOGRAPHIC DIAGNOSIS

- Mild synovitis and effusion
- Diffuse thickening of the cranial cruciate ligament without rupture
- No ultrasonographic evidence of meniscal injury

HOSPITAL NAME

Franklin Animal Clinic

INTERPRETATION OF FINDINGS & FURTHER RECOMMENDATIONS

REFERRING VET

Sam Doverspike

Overall, the findings may indicate early cranial cruciate ligament disease such as edema /pre-rupture stage of cranial cruciate ligament disease or early partial rupture. Fiber continuity may be preserved despite underlying degenerative or inflammatory changes. No ultrasonographic evidence of meniscal injuries identified.

INVOICE

23831

Clinical monitoring is advised as early cranial cruciate ligament disease is often progressive even when initial response to NSAIDs is favorable. Consider repeat ultrasound or advanced imaging such as MRI or arthroscopy if lameness persists or worsens or becomes less responsive to conservative management.

DATE

02/06/2026



PATIENT

Koda Kiefer

SPECIES

Canine

BREED

Golden Retriever

SEX

MN

AGE

2yr

INTERPRETED BY

Nele Eley (Ondreka),
DVM Dr. med. vet.,
DipECVDI

HOSPITAL NAME

Franklin Animal Clinic

REFERRING VET

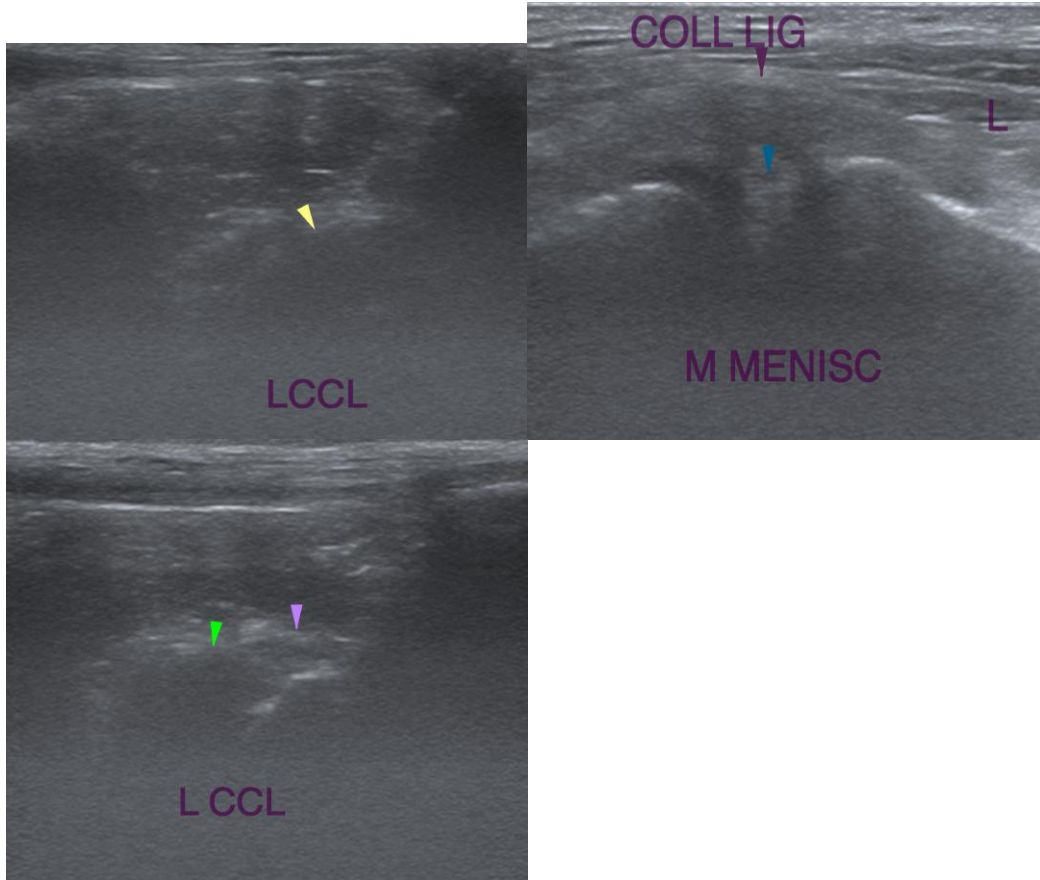
Sam Doverspike

INVOICE

23831

DATE

02/06/2026



The information and recommendations provided are based on the images presented by the referring veterinarian. No evaluation can be communicated regarding pathology that was not visible in the image/video clips provided.

Thank you for this referral. If the clinical or image interpretation does not parallel your findings or if I can be of any further assistance please contact me.

Nele Eley (Ondreka), DVM, Dr. med. vet., DipECVDI
European Specialist in Veterinary Diagnostic Imaging, Cert. Radiology,
Senior lecturer University of Giessen/Germany, Veterinary Faculty, Department of Radiology.
info@sonopath.com



PATIENT

Koda Kiefer

SPECIES

Canine

BREED

Golden Retriever

SEX

MN

AGE

2yr

INTERPRETED BY

Nele Eley (Ondreka),
DVM Dr. med. vet.,
DipECVDI

HOSPITAL NAME

Franklin Animal Clinic

REFERRING VET

Sam Doverspike

INVOICE

23831

DATE

02/06/2026